PRM+
JOURNAL OF QUANTITATIVE RESEARCH IN REHABILITATION MEDICINE

PRM+ 1 (2018) 24-27

Role of pelvic asymmetry in skeletal posture

Jussi Timgren MD [1]

Abstract

Objectives

To investigate the signs of pelvic asymmetry in skeletal posture and to describe three novel maneuvers directed at iliac asymmetry, sacral torsion, and iliosacral inflare/outflare.

Methods

Retrospective study of consecutive patients with musculoskeletal complaints. A palpation Meter® tool was used to examine the position of iliac crests and inferior scapular angles. The patients performed three self-correcting muscle-energy maneuvers.

Results

There were 103 patients (37 men, age 12 to 80 years). Reversible pelvic obliquity was found in 100 (97.1%) patients. Iliac asymmetry was associated with anteriorly rotated ilium in 51% with ipsilateral leg lengthening. The 49% had an upslip of the ilium associated with leg shortening. The 53 patients were re-examined and, of them, 84% demonstrated improved pelvic alignment.

Conclusions

Reversible pelvic obliquity in patients with musculoskeletal pain might be more common than commonly assumed. This study proposes three novel maneuvers as an alternative to conventional manual treatment of pelvic obliquity.

Keywords:

sacroiliac joint, scoliosis, pelvis, pelvic tilt, malalignment

INTRODUCTION

In 1936, Pitkin and Pheasant have described the malalignment syndrome of pelvis – "sacrarthrogenetic telalgia" (1). It comprises three features: a dysfunctional sacroiliac joint causing referred pain in lower extremities, an oblique sacrum resulting in compensatory spinal scoliosis, and an asymmetrical position of bones appearing as leg length discrepancy. Pitkin and Pheasant have suggested a treatment aiming at restoring pelvic alignment, equalizing leg length, and straightening out scoliosis. In 1980, DonTigny has proposed an anteriorly rotated dysfunction of the sacroiliac joint might cause pelvic obliquity, a high iliac crest, an apparent lengthening of the ipsilateral leg, and a laterally deviated lumbar spine contributing to developing low back pain (2). DonTigny has suggested that sacroiliac joint mobilization might correct the disorder. Schamberger has advised the reversable nature of pelvic obliquity and its relationship with leg length discrepancy and functional scoliosis (3). He has described the relationship between the asymmetrical alignment of pelvis, trunk, and extremities and asymmetrical weight-bearing patterns, diminished ranges of motion, and increased tension in muscles, tendons, and ligaments. In line with earlier literature on manual therapy, he has referred to three possible malalignments of pelvic bones: iliac asymmetry (either rotatory malalignment or upslip); sacral torsion around a diagonal axis; and iliosacral inflare or outflare (medially or laterally rotated ilium). Schamberger has believed that malalignment of pelvis and/or spine is presented in 80% to 90% of total adult population and might be responsible for back pain in 50% to 60% of the cases (4).

Several studies have investigated sacroiliac joint dysfunction, functional scoliosis, and leg length discrepancy as separate entities. However, the possible interdependency of these three conditions has received only little attention. Our previous study demonstrated that even 80% of patients visiting a specialist in PRM might have reversible pelvic asymmetry related to back (5). The objective of present study was to describe the signs of pelvic asymmetry and to introduce three novel maneuvers directed at iliac asymmetry, sacral torsion, and iliosacral inflare or outflare using patients' own muscular effort without mobilization performed by a physician.

METHODS

This was a retrospective study of patients visiting a private doctor's office (a specialist in PRM) in 2017 due to back pain. The consecutive medical records were retrieved for the analysis. No additional examination or intervention related explicitly to the study have been performed. Thus, no approval from an ethical board was needed. The assessment of three possible pelvic malalignments were added to a usual PRM examination: 1) a sagittal iliac

[1] Part time private doctor's office (retired), Järvenpää, Finland
Conflicts of interest: None to declare
Corresponding author: Laurilantie 89, FI-04480 Haarajoki, Finland. Tel. +358 50 596 8960. Email jussi.timgren@pp.fimnet.fi

asymmetry, 2) a sacral torsion around a diagonal axis, and 3) transverse iliosacral inflare or outflare. The patients were instructed to perform three muscle-energy aligning maneuvers. The assessment was performed before and after maneuvers.

To measure the level of iliac crests and inferior scapular angles, Palpation Meter (PALM®, Performance Attainment Associates, Roseville, MN, USA) was used. This instrument has been found to be valid, reliable, and precise tool to measuring scapular position (6,7) and pelvic crest height difference (8-10). It combines a calliper and an inclinometer that produce an estimate using a sine function slide ruler. A 12-mm thick wooden plate was used to compare a leg length in up-right position.

Examination steps

Step 1. Iliac asymmetry

A physician sought after three possible findings: a height of iliac crests, a height of scapulae, and an anteroposterior position of shoulders. Leg length discrepancy was estimated in supine position placing assessor's thumbs caudal to the medial malleoli and comparing the thumbs' position. If discrepancy was identified, then a 12-mm elevating block under a patient foot was placed when standing and the iliac crest height was compared. Figure 1 shows the procedure applied in iliac alignment.

Step 2. Sacral torsion

Iliac crest level was re-assessed using a PALM® tool. If ilia had become even, then the observed symmetry was confirmed by placing 12-mm blocks under each foot in order to achieve equal elevation in both iliac crests. After that, the level of the inferior scapular angles was measured, and the anteroposterior relationship of inferior sacral lateral angels and shoulders was compared. Asymmetry observed in all three points was considered to indicate sacral torsion and a patient was instructed to perform a sacrum aligning maneuver (Figure 2). Subsequently, the height of the scapular angles was measured in up-right position and the anteroposterior relationship of the lateral and inferior sacral angles and shoulders was reassessed. If all of these three factors showed symmetry while a spine was still asymmetric, an Adam's forward flexion test was performed to detect possible idiopathic scoliosis.

Step 3. Inflare and outflare

After iliac crests and sacrum were aligned, the "standing forward flexion test" was performed. An assessor placed his thumbs on a patient's posterior superior iliac spine with a patient bending forward. The cephalad asymmetrical movement of one of the posterior superior iliac spines indicated sacroiliac joint dysfunction on that side. Later, a patient's feet position was assessed in supine position. More outward rotated foot on the side of positive flexion test was considered to indicate iliosacral outflare and more inward rotated foot was considered to indicate inflare.

Figure 1. Maneuver for iliac asymmetry
While lying supine, one half of the pelvis is steadily drawn cephalad until maximal effort is achieved, for 2-3 seconds in total. This maneuver is primarily a contraction of quadratus lumborum. The same movement is performed on the opposite side and repeated three times.

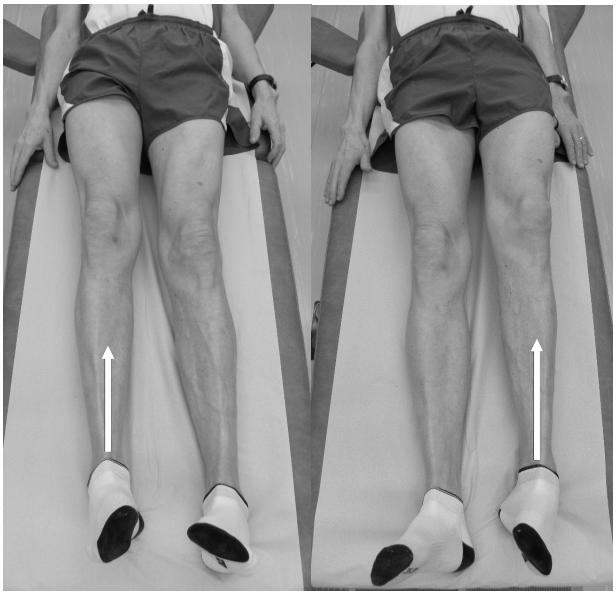

Figure 3 describes the procedure a patient was asked to perform when both these signs were positive.

All three maneuvers were performed to the full range of motion, with maximal strength, and without sudden tugging movements. The patients were instructed to continue with the aligning movements once a day and gradually, less frequently.

Additional video file is available from XXX.com

Figure 2. Maneuver for sacral asymmetry
Lying supine, the patient performs hip extensor activation with an extended knee by pressing the calf and heel against the plinth until maximal effort is reached. The same procedure is performed with the opposite leg and repeated three times.

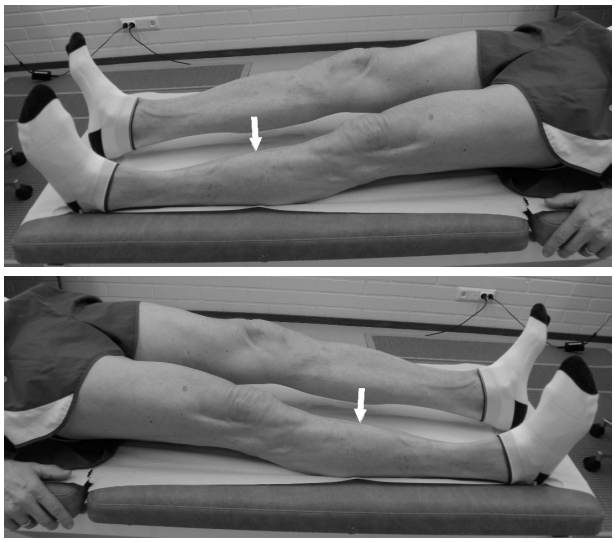

RESULTS

The age of the 103 patients ranged from 12 to 80 years, 37 were men. Reversible iliac asymmetry was found in 100 out of 103 patients (97%). Fifty-one patients had an anteriorly rotated ilium; 45 on the left side and six on the right side. Forty-nine patients had an upslip; 35 on the left side and 14 on the right side. Both asymmetries were associated with a higher ilium on the affected side. The measured height difference between the iliac crests using a PALM® tool was 20 (10 to 28) mm. The average

Figure 3. Maneuver for inflare/outflare
The aligning movement is made with the patient lying supine, having slightly adducted outstretched legs, with subsequent maximal activation of the inner and outer rotators of the hips. The feet are rotated inwards bringing the big toes as close to one another as possible until the maximal muscle strength is reached. Thereafter, the feet are rotated, with the big toes turned outwards as far as possible in the same equal manner. The procedure is repeated three times.

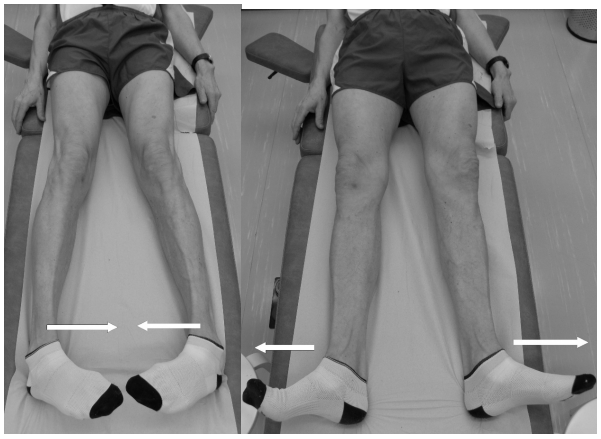

difference in height of scapular angles was 12 (0 to 20) mm. Table 1 presents positional differences between iliac anterior rotation and upslip. When rotated anteriorly, the 12-mm lift under the ipsilateral leg was associated with the iliac crest to be further elevated, while in upslip, the placement of the lift under the side of the upslip was associated with the iliac crest iliac crest descending to the level of the opposite side. This observation seemed paradoxical. A sacral torsion (noticeable after adjusting the ilia) was observed in 98 patients. The average difference in heights of scapular elevation was 9 (6 to 16) mm. In 29 cases, scapular elevation was on the opposite to sacral torsion side. Otherwise, scapular elevation was on the same side as the elevation associated with a sacral torsion. Fifty-one patients were tested positive for sacroiliac outflare or inflare: 39 patients had right and 11 had left outflare and one patient had left inflare. In all the cases, the proposed maneuvers resulted in corrected sacroiliac malalignment.

Fifty-one patients were re-tested at their second visit to a doctor. Of them, alignment was apparently achieved concerning all three possible malalignments in 43 (84 %) patients. Of eight patients with sacral asymmetry at the second assessment, three had an anterior iliac rotation with sacral torsion, three had a sacral torsion, one had a sacral torsion with outflare, and one patient had inflare.

Table 1. Positional differences between iliac anterior rotation and upslip.

	Anterior rotation	Upslip
Standing with the body weight equally on both feet	Ipsilateral iliac crest and contralateral scapula, higher. Contralateral shoulder, more anterior	Ipsilateral iliac crest and scapulae, higher. Shoulder, more anterior.
Standing on a lift (height 12 mm) under the contralateral foot	Iliac crests are even	Contralateral iliac crest elevated
Standing on a lift (height 12 mm) under the ipsilateral foot	Ipsilateral iliac crest further elevated	Iliac crests are even
Lying in the supine position	Ipsilateral leg longer	Ipsilateral leg shorter

DISCUSSION

The results of this retrospective observational study suggest that a dysfunctional sacroiliac joint may result in pelvic asymmetry associated with sacroiliac malalignment. All three the proposed maneuvers seemed to correct sacral asymmetry. The high prevalence of reversible pelvic obliquity observed in this study was in line with the results of Schamberger, who has reported that the malalignment of the pelvis and spine might exist in up to 90% of adults. Also, as reported by Shaw, even 98% of patients with low back pain might have mechanical dysfunction of sacroiliac joint presented as pelvic malalignment and leg length discrepancy (11).

The physiological movement of the sacroiliac joint comprises the combination of rotation and translation. Studies report the amount of rotation and translation to range from 1–4º and 1–3 mm, respectively (12). The diagnosis of sacroiliac joint dysfunction has remained controversial. Stovall and Kumar have suggested that palpating anatomical landmarks is an unreliable approach to assessing innominate symmetry (13). Moreover, sacroiliac joint pain provocation tests and mobility tests are considered unreliable for the diagnosis of sacroiliac joint dysfunction. The generalization of the results of the study might be limited by the fact that this was a retrospective study amongst patients treated by a single physician. The same physician performed also all the assessments.

Further research is needed to confirm the observed results. Controlled studies with at least single-blinded design are required to verify the effects of maneuvers suggested by the author.

CONCLUSIONS

Reversible pelvic obliquity in patients with musculoskeletal pain might be more common than commonly assumed. This study proposes three novel maneuvers as an alternative to conventional manual treatment of pelvic obliquity.

REFERENCES

1. Pitkin H, Pheasant H. Sacrarthrogenetic telalgia II. A study of sacral mobility. J Bone Joint Surg 1936;18(2):365-74
2. DonTigny. Anterior dysfunction of the sacroiliac joint as a major factor in the etiology of idiopathic low back pain. Phys Ther 1990;70(4):250-62
3. Schambeger W. The malalignment syndrome, diagnosing and treating a common cause of acute and chronic pelvic, limb and back pain. London Churchill Livingstone; Second edition 2013.
4. Schambeger W. The malalignment syndrome, diagnosing and treating a common cause of acute and chronic pelvic, limb and back pain. London Churchill Livingstone; 2013. p. 1
5. Timgren J, Soinila S. Reversible pelvic asymmetry. J Manipulative Physiol Ther 2006;29(7):561-5
6. Rondeau W. The Accuracy of the Palpation Meter (PALM) for measuring scapular position in overhead athletes, dissertation. Chapel Hill: University of North Carolina; 2007. [Available from: https://search.proquest.com/openview/334c2035409c1ce7dcf308ec2fce715b/1?pq-origsite=gscholar&cbl=18750&diss=y accessed 20-April-2018]
7. da Costa B, Armijo-Olivo S, Gadotti I, Warren S, Reid D, Magee D. Reliability of scapular positioning measurement procedure using the Palpation Meter (PALM). Physiotherapy 2010;96(1):59-67
8. Petrone M, Guinn J, Sutlive T, Reddin, A, Flynn TW, Garber MP. The accuracy of the Palpation Meter (PALM) for measuring pelvic crest height difference and leg length discrepancy. J Orthop Sports Phys Ther 2003;33(6):319-25
9. Hagins M, Brown M, Cook C, et al. Intratester and Intertester Reliability of the Palpation Meter (PALM) in Measuring Pelvic Position. The Journal of Manual & Manipulative Therapy. 1998;6(3):130-136
10. Azevedo D, Santos H, Carneiro RL, Andrade GT. Reliability of sagittal pelvic position assessments in standing, sitting and during hip flexion using palpation meter. J Bodyw Mov Ther 2014;18(2):210-4
11. Shaw J. The role of sacroiliac joint as a cause of low back pain and dysfunction. In: Vleeming A, Mooney V, Snijders C, Dorman T, eds. Proceedings from the First Interdisciplinary World Congress on Low Back Pain and its Relation to Sacroiliac Joint. San Diego; 1992
12. Lee D. The evolution of myths and facts regarding function and dysfunction of the pelvic girdle. In: Vleeming A, Mooney V, Stoeckart R, editors. Movement, stability & lumbopelvic Pain. Edinburgh: Churchill Livingstone; 2007. p. 194
13. Stovall BA, Kumar S. Anatomical landmark asymmetry assessment in the lumbar spine and pelvis: a review of reliability. PM R. 2010;2(1):48-56

Acknowledgments
The author thanks Elsevier Language Editing Services for revising the language.